Histopathology of Pediatric Nonalcoholic Fatty Liver Disease

Jeffrey B. Schwimmer,[1,5] Cynthia Behling,[2] Robert Newbury,[6] Reena Deutsch,[3] Caroline Nievergelt,[4] Nicholas J. Schork,[4] and Joel E. Lavine[1,5]

Nonalcoholic fatty liver disease (NAFLD) and nonalcoholic steatohepatitis (NASH) are common in children and adolescents. However, standard histological criteria for pediatric NAFLD and NASH are undeveloped. We reviewed consecutive patients ages 2 to 18 years with biopsy-proven NAFLD diagnosed between 1997 and 2003. Biopsies were evaluated by two pathologists for individual features of steatohepatitis. Agglomerative hierarchical cluster analysis demonstrated two different forms of steatohepatitis. Type 1 was characterized by steatosis, ballooning degeneration, and perisinusoidal fibrosis; type 2 was characterized by steatosis, portal inflammation, and portal fibrosis. The study included 100 children with NAFLD. Simple steatosis was present in 16% of subjects, and advanced fibrosis was present in 8%. Type 1 NASH was present in 17% of subjects, and type 2 NASH was present in 51%. Boys were significantly ($P < .01$) more likely to have type 2 NASH and less likely to have type 1 NASH than girls. The NASH type differed significantly ($P < .001$) by race and ethnicity. Type 1 NASH was more common in white children, whereas type 2 NASH was more common in children of Asian, Native American, and Hispanic ethnicity. In cases of advanced fibrosis, the pattern was generally that of type 2 NASH. In conclusion, type 1 and type 2 NASH are distinct subtypes of pediatric NAFLD, and type 2 is the most common pattern in children. NASH subtypes should be considered when interpreting liver biopsies and planning studies of the pathophysiology, genetics, natural history, or response to treatment in pediatric NAFLD. (Hepatology 2005;42:641-649.)

See Editorial on Page 536

Nonalcoholic fatty liver disease (NAFLD) is a clinicopathological diagnosis characterized histologically by accumulation of macrovesicular fat in hepatocytes in a patient in whom other causes of liver disease (including chronic alcohol use) are excluded. NAFLD is likely the most common cause of chronic liver disease in children.[1] The major risk factors are obesity and insulin resistance,[2] and the prevalence of these risk factors has increased rapidly in children throughout the world.[3] NAFLD is rapidly becoming an important problem. Undiagnosed, this condition may progress silently and result in cirrhosis, portal hypertension, and liver-related death in early adulthood.[4]

The characteristic histological features of NAFLD range from steatosis alone to steatohepatitis (NASH) with or without fibrosis to cirrhosis. In adults, the histological features of NAFLD have been well-described and include macrovesicular steatosis, perisinusoidal or pericellular fi-

Abbreviations: NAFLD, nonalcoholic fatty liver disease; NASH, nonalcoholic steatohepatitis; BMI, body mass index; QUICKI, quantitative insulin sensitivity check index; HOMA-IR, homeostasis model assessment of insulin resistance; ALT, alanine aminotransferase.

From the [1]Division of Gastroenterology, Hepatology, and Nutrition, Department of Pediatrics, the Departments of [2]Pathology and [3]Family and Preventative Medicine, and the [4]Polymorphism Research Laboratory, Department of Psychiatry, University of California–San Diego School of Medicine, San Diego, CA; and the Departments of [5]Gastroenterology and [6]Pathology, Children's Hospital and Health Center, San Diego, CA.

Received April 26, 2005; accepted June 20, 2005.

Supported by a grant from the Rest Haven Foundation and by Grant M01 RR00827 from the National Center for Research Resources of the National Institutes of Health for the General Clinical Research Center at the University of California–San Diego.

Address reprint requests to: Joel E. Lavine, M.D., Ph.D., University of California, San Diego, 200 West Arbor Drive, San Diego, CA 92103-8450. E-mail: jolavine@ucsd.edu; fax: 619-543-7537.

Copyright © 2005 by the American Association for the Study of Liver Diseases.

Published online in Wiley InterScience (www.interscience.wiley.com).

DOI 10.1002/hep.20842

Potential conflict of interest: Nothing to report.

brosis, foci of lobular inflammation, lipid granulomas, Mallory hyaline, and megamitochondria.[5] The combination of macrovesicular steatosis with ballooning change of hepatocytes and/or perisinusoidal fibrosis constitutes a pattern of histology considered diagnostic of NASH in an appropriate clinical context.[6]

In contrast, standard criteria for the diagnosis of NAFLD or NASH in children are undeveloped. Furthermore, pediatric studies of NAFLD have described patterns of inflammation and fibrosis that differ from those reported in adults with NAFLD.[7] A major pitfall of these studies is the small sample size and/or nonuniform reporting of histopathology features.[8-11] Given the considerable difference in age at presentation, one can postulate that NAFLD in children is distinct from NAFLD in adults. Such distinctions may extend to pathophysiology, clinical course, or treatment response.

We have previously suggested that there are important differences between children and adults in the histological features associated with NASH.[12] The goal of this study was to define the liver biopsy findings in a large series of children with clinical features consistent with NAFLD. We sought to define distinct patterns of nonalcoholic steatohepatitis (NASH) in children, determine their prevalence, and test potential associations.

Materials and Methods

Subjects and Clinical Data Collection. We identified subjects who were 18 years of age or less with biopsy-proven NAFLD at Children's Hospital, San Diego, from January 1997 through April 2003. From 1997 to 2002, subjects were identified via retrospective chart review obtained with a waiver of consent. Detailed clinical data on a subset of these subjects was previously reported.[2] During 2002-2003, subjects were identified prospectively through the Fatty Liver Clinic at Children's Hospital. For those subjects, written subject assent and parental consent were obtained. The protocol was approved by the institutional review boards of the University of California–San Diego and Children's Hospital, San Diego.

In all subjects the diagnosis of NAFLD was made following the exclusion of causes of chronic hepatitis including hepatitis B, hepatitis C, alpha-1 antitrypsin deficiency, autoimmune hepatitis, Wilson's disease, drug toxicity, total parenteral nutrition, and chronic alcohol intake. Charts for all subjects were reviewed for age, sex, race, ethnicity, weight, and height. Body mass index (BMI) was calculated as the weight (kg) divided by the height (m) squared. Weight status was determined using the Centers for Disease Control and Prevention 2000 growth curves and defined as underweight (BMI $\leq$ 5th percentile), healthy weight (BMI $>$ 5th and $<$ 85th percentile), overweight (BMI $\geq$ 85th percentile), and obese (BMI $\geq$ 95th percentile). Results of liver chemistry obtained at the time of biopsy were recorded (serum aspartate aminotransferase, alanine aminotransferase, alkaline phosphatase, γ-glutamyltransferase).

Fasting insulin and glucose also were recorded. Impaired insulin sensitivity (termed *insulin resistance*) has been defined as being the insulin sensitivity of the lowest 10% of a nonobese, nondiabetic population.[13] We used a mathematical model for insulin sensitivity, the quantitative insulin sensitivity check index (QUICKI),[14] that was the reciprocal of the log(fasting insulin (μU/mL)) + log(fasting glucose (mg/dL)). We also calculated insulin resistance using the homeostasis model assessment of insulin resistance (HOMA-IR), which was defined as fasting insulin (μU/mL) $\times$ fasting glucose (mmol/L) / 22.5.[15] Although other models exist, we chose these two models because we have previously demonstrated their relationship to steatosis and fibrosis in children with NAFLD.[2] For children, impaired insulin sensitivity is defined as QUICKI $<$ 0.339[16] and is reliable in both the euglycemic and hyperglycemic range. Insulin resistance is defined as HOMA-IR $>$ 2.0. Although QUICKI and HOMA-IR are algebraically related, the information provided by each may be unique.[2]

Histopathology. Liver biopsies were performed by percutaneous sampling of the right lobe with a 15-gauge needle. All biopsies were 1.5 cm or more in length. Sections were stained with hematoxylin-eosin, periodic acid Schiff, periodic acid Schiff– digested, iron stain, and Masson trichrome reagents and evaluated by a hepatopathologist and a pediatric pathologist (C. B. and R. N.). The pathology evaluation was performed masked from any clinical information. The biopsies were reviewed by both pathologists at a double-headed microscope, and the assignment of histological value for each feature was agreed upon and recorded. The presence and severity of histological features of steatohepatitis were determined. Steatosis was reported as the percentage of hepatocytes containing macrovesicular fat (fat droplet equal to or larger than the size of the nucleus, often displacing the nucleus) or microvesicular fat (numerous small fat droplets surrounding a centrally located nucleus). Quantitative steatosis was graded as mild (5%-33%), moderate (34%-66%), or severe (67%-100%).

Additional histological features noted included the presence or absence of balloon degeneration of hepatocytes, Mallory hyaline, glycogen nuclei, megamitochondria, lipogranulomas, and iron. Perisinusoidal fibrosis was noted as present or absent. Portal inflammation was graded as 0 (none), 1 (mild, sprinkling of lymphocytes in

Table 1. Definition for NASH Types

	Type 1			Type 2		
Ballooning degeneration	+	+	−	−		
Perisinusoidal fibrosis	−	+	+	−		
Steatosis	+			+		
Portal inflammation	−			+	+	−
Portal fibrosis	−			−	+	+

+, feature is present; −, feature is absent.

some or all portal tracts), 2 (moderate, denser lymphocytic infiltrate in most portal tracts), or 3 (severe, dense lymphocytic infiltrate in most or all portal tracts). Portal fibrosis was evaluated on the trichrome stained slides according to the METAVIR criteria[5] as 0 (none), 1 (mild = portal expansion), 2 (moderate = portal fibrosis with septa), 3 (severe = portal–portal or portal–central bridging septae without regenerative nodules), and 4 (cirrhosis = bridging fibrosis with regenerative nodule formation).

Definition of Type 1 and Type 2 NASH. A specific study goal was to create a histological definition for pediatric NASH. Based on our previous preliminary data, we defined two distinct injury patterns compatible with steatohepatitis. The first pattern is consistent with NASH as described in adults. We termed this pattern "type 1" NASH and defined it as the presence of steatosis with ballooning degeneration and/or perisinusoidal fibrosis in the absence of portal features. The second pattern was termed "type 2" NASH and was defined as the presence of steatosis along with portal inflammation and/or fibrosis in the absence of ballooning degeneration and perisinusoidal fibrosis (Table 1).

Data Analysis. Means, standard deviations, medians, ranges, and percentages were reported for various demographic and clinical features. In characterizing the relationships between steatosis and histopathology features, Spearman rank correlation was used for portal fibrosis, portal inflammation, and perisinusoidal fibrosis. Student *t* tests were used for all other features. Student *t* tests, linear regression, and the Welch test for unequal variances were used to identify relationships between the severity of portal fibrosis and features.

Cluster analysis was pursued using agglomerative hierarchical clustering.[17] The histopathological features used to define NASH types (ballooning degeneration, perisinusoidal fibrosis, portal inflammation, portal fibrosis) were used to derive a dissimilarity matrix for all the subjects using squared Euclidean distance as a measure of dissimilarity. The dissimilarity matrix then was analyzed for hierarchical clustering among the study subjects using the average linkage measure for agglomerating the clusters.[17] Coherence of the clusters and the likely number of meaningful clusters were assessed by comparing individuals assigned to clusters across the available ancillary information (*e.g.*, age, race, obesity level, additional histopathological phenotypes, and so forth). This strategy therefore does not rely on purely statistical criteria among the items used in the cluster analysis to gauge cluster coherence and cluster number—a strategy fraught with several statistical and interpretive problems—but rather gauges the biological meaningfulness of the clusters from ancillary, but appropriate, clinical and biological perspectives. This strategy was introduced in the literature by Schork and colleagues in the context of assessing genetic background heterogeneity effects in age-related disease and longevity.[18]

Results

Demographic and Clinical Features. There were 106 children with a clinical phenotype and histopathology compatible with a diagnosis of NAFLD. In 6 subjects, the potential diagnosis of NAFLD was noted in conjunction with a concurrent or preceding condition that could sufficiently influence liver histology, which excluded them from further analysis: history of hepatitis C virus infection (1), autoimmune hepatitis (1), and history of malignancy (leukemia 2, hepatoblastoma 2). The remaining 100 subjects (65 boys, 35 girls) were included in the analysis; their clinical characteristics are detailed in Table 2. The median age for children with NAFLD was 12 years (range: 2-18). The majority (92%) of children were obese, with the remainder being underweight (1%), healthy weight (1%), and overweight (6%). The median BMI for the entire cohort was 30.7 kg/m^2 (range: 15.4-60.4). Type 2 diabetes mellitus was present in 8% of subjects. Most subjects had mildly abnormal serum aminotransferase activity, although values ranged from normal to markedly elevated; median and ranges were alanine aminotransferase (ALT) 79 (16-664), aspartate aminotransferase 53 (22-273), and γ-glutamyltransferase 47 (9-194). All subjects had normal total and direct bilirubin values. Hypertriglyceridemia and insulin resistance were common.

Descriptive Histopathology. The amount of steatosis ranged from 5% to 100% with a mean of 64 ± 28% steatotic hepatocytes. The distribution of steatosis across the cohort was mild in 19%, moderate in 28%, and severe

Table 2. Clinical Characteristics of Children With NAFLD

Characteristic	All Subjects (n = 100)	Simple Steatosis (n = 16)	Overlap (n = 16)	Type 1 NASH (n = 17)	Type 2 NASH (n = 51)
Age, mean (SD), y	12.0 (3.0)	12.3 (4.3)	11.5 (3.2)	13.5 (2)	11.5 (2)
Sex, n (%)					
Boys	65 (65)	10 (62.5)	11 (69)	6 (35)	38 (75)
Girls	35 (35)	6 (37.5)	5 (31)	11 (65)	13 (25)
Race/Ethnicity, n (%)					
Asian	10 (10)	3 (19)	1 (6)	0 (0)	6 (12)
Black, non-Hispanic	3 (3)	2 (12.5)	0 (0)	0 (0)	1 (2)
Hispanic	67 (67)	9 (56)	14 (88)	7 (41)	37 (73)
Native American	5 (5)	0 (0)	0 (0)	1 (6)	4 (8)
White, non-Hispanic	14 (14)	2 (12.5)	1 (6)	9 (53)	2 (4)
Other	1 (1)	0 (0)	0 (0)	0 (0)	1 (2)
BMI (kg/m^2)					
Mean (SD)	31.6 (6.9)	29.1 (7.7)	32.7 (7)	30.7 (5)	31.8 (7)
Z-score, mean (SD)	2.3 (0.7)	2.1 (1.4)	2.5 (0.7)	2.1 (0.4)	2.3 (0.3)
Laboratories, mean (SD)					
AST (U/L)	65 (43)	52 (30)	79 (52)	79 (34)	65 (47)
ALT (U/L)	104 (91)	69 (35)	131 (115)	119 (58)	106 (104)
GGT (U/L)	58 (38)	37 (17)	61 (36)	59 (33)	66 (44)
Triglyceride (mg/dL)	181 (88)	161 (104)	192 (63)	195 (98)	174 (89)
QUICKI	0.289 (0.03)	0.299 (0.04)	0.290 (0.02)	0.285 (0.02)	0.287 (0.03)
HOMA-IR	11.0 (10.9)	9.2 (8.3)	7.8 (4.0)	10.8 (10.3)	10.7 (8.7)

Abbreviations: AST, aspartate aminotransferase; ALT, alanine aminotransferase; GGT, γ-glutamyltransferase.

in 53% of subjects. Lipogranuloma (83%) and glycyogenated nuclei (55%) were present in most biopsy specimens. Portal inflammation, although typically mild, was present in the majority (70%) of children. Portal fibrosis was present in 60% of subjects, with moderate to severe fibrosis in half of these individuals. Features commonly described in adults with NASH such as ballooning degeneration (24%), Mallory's hyaline (19%), lobular inflammation (36%), and perisinusoidal fibrosis (30%) were less commonly noted and typically found within the same biopsy. Cirrhosis was present in 3%.

The severity of portal fibrosis was correlated to both clinical and histopathology features. Subjects with stage 3 or 4 portal fibrosis (n = 8) were significantly ($P < .01$) younger, had higher serum GGT, and a greater degree of insulin resistance than those subjects with lesser stages of fibrosis. Those subjects with portal fibrosis classified as none or mild (n = 72) had significantly ($P < .02$) less fat on biopsy (59 ± 30%) compared with those subjects with moderate to severe portal fibrosis (n = 28; 73 ± 17%). The severity of portal fibrosis was significantly related to the presence of both lipogranulomas ($P = .03$) and portal inflammation ($P < .0001$).

Type 1 and Type 2 NASH. The results of the agglomerative hierarchical cluster analysis are depicted in Fig. 1. The majority of biopsies (84%) demonstrated a distinct pattern, separating cleanly into the categories of simple steatosis, type 1 NASH, or type 2 NASH. Type 2 NASH was more common (51/100) than type 1 NASH (17/100). In seven of the eight cases of advanced fibrosis, the histology was that of type 2 NASH. In the remaining case, the biopsy showed overlap with both type 1 and type 2 NASH. The typical perisinusoidal fibrosis and ballooning degeneration of hepatocytes seen in type 1 NASH are illustrated in photographs of two cases in Fig. 2. The typical histological pattern of type 2 NASH is demonstrated in photographs of six different cases in Fig. 3.

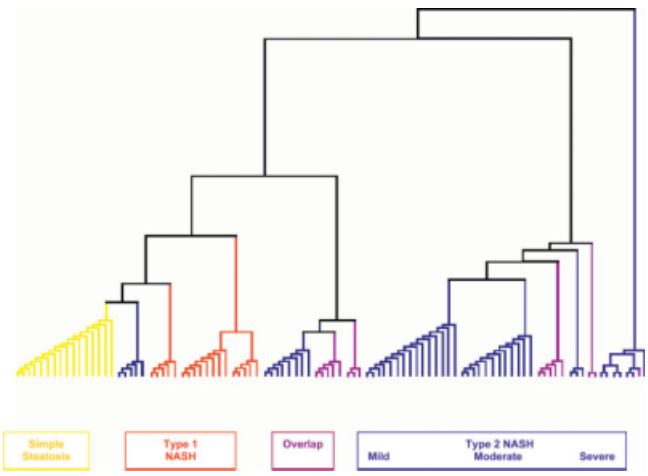

Fig. 1. Dendrogram of pediatric NAFLD. The subtypes of NAFLD were determined using agglomerative hierarchical clustering based on the features of ballooning degeneration, perisinusoidal fibrosis, portal inflammation, and portal fibrosis. Each end line represents a single case and is color-coded to represent the histopathology category. Overlap represents those biopsies that demonstrated steatosis along with at least one feature from type 1 and type 2 NASH. Type 2 NASH was labeled as mild, moderate, or severe based on the degree of portal fibrosis. NASH, nonalcoholic steatohepatitis.

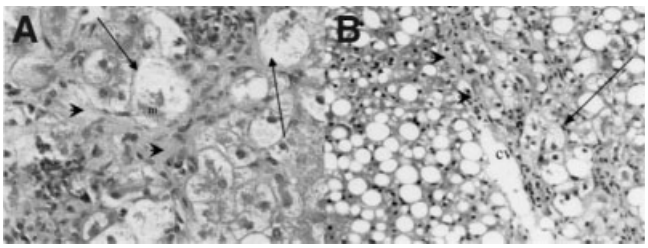

Fig. 2. Typical histologic appearance of type 1 NASH in children. These photomicrographs illustrate the typical features of classic or type 1 NASH in biopsies from two different obese children. Ballooned hepatocytes are conspicuous (arrows) with Mallory hyaline identifiable in the cytoplasm of the ballooned hepatocyte (panel A, m). Perisinusoidal fibrosis is notable (arrowheads). m, Mallory; cv, central vein.

Other features noted in type 2 NASH are illustrated in Fig. 4. Specifically, the type 2 NASH pattern consistently spared the central vein and showed no zone 3 hepatocyte injury, and the portal inflammation was predominantly lymphocytic. Some cases demonstrated marked zonal distribution of the steatosis, with zone 1 fat sparing (Fig. 4D-F).

In 16% of subjects, the histopathology did not meet the criteria for simple steatosis, type 1 NASH, or type 2 NASH and thus were deemed as overlap or indeterminate (Table 2). As shown in Fig. 1, in 8 of the 16 cases the histopathology clustered on the same main branch as type 1 NASH. In 7 of the 16 cases, the histopathology clustered with mild to moderate type 2 NASH. In 1 case, the histopathology clustered with severe type 2 NASH. Over-

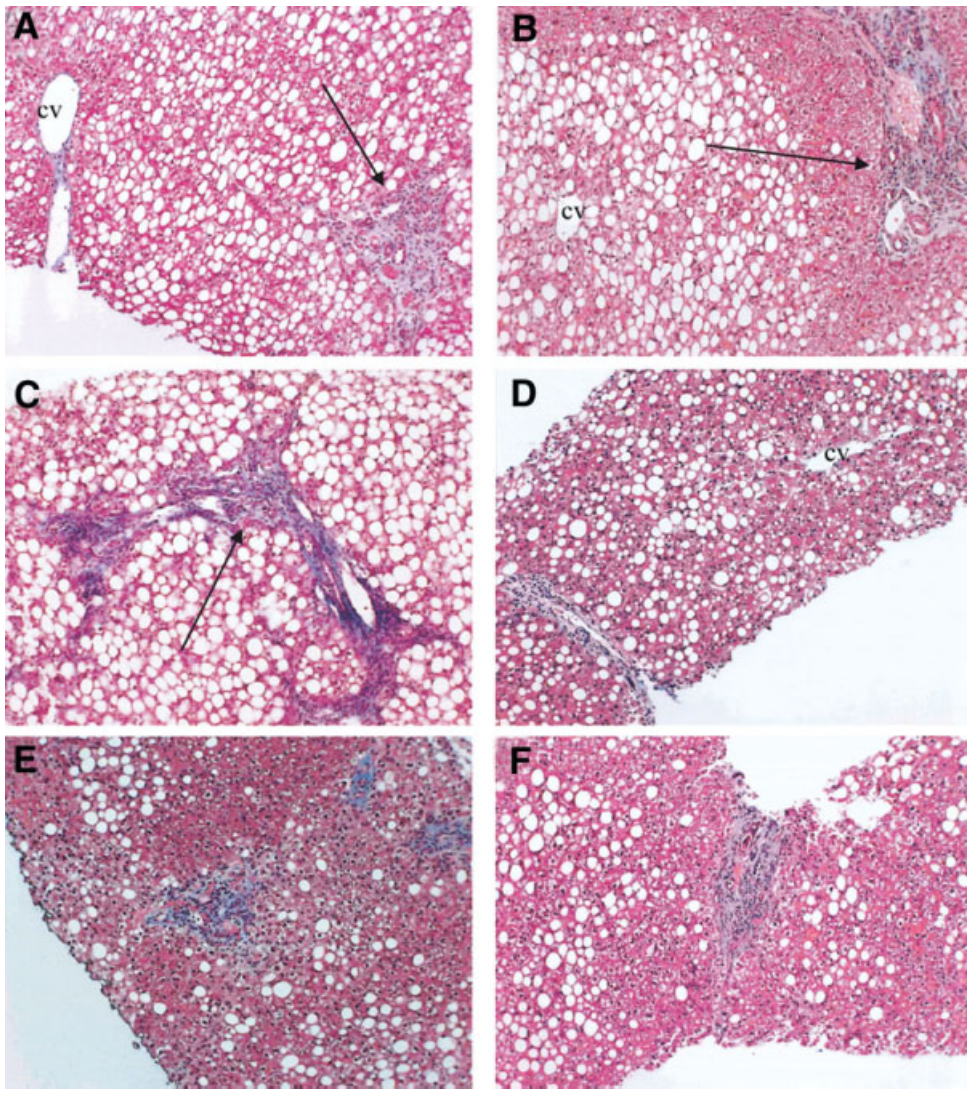

Fig. 3. Typical histologic appearance of type 2 NASH in children. These panels represent histological findings from six different obese children with nonalcoholic fatty liver disease. The identifiable pattern consists of moderate to marked steatosis, with portal inflammation or fibrosis and the absence of ballooning degeneration and perisinusoidal/perivenular fibrosis. (A-C) Portal fibrous expansion (arrows) with fibrous septa present in panel C. Central veins are free of fibrosis. Original magnification, ×100. cv, central vein.

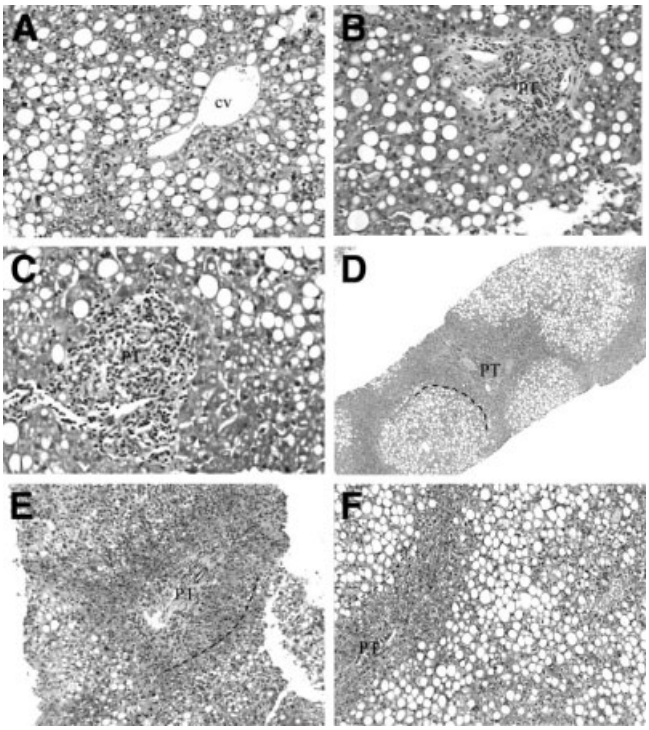

Fig. 4. Specific histological findings in children with type 2 NASH. These photomicrographs further illustrate findings in liver biopsies from children with the type 2 pattern. (A) Central veins consistently show no evidence of injury or fibrosis. (B-E) Predominately lymphocytic portal inflammation is present (B-C) with early portal fibrous expansion (D-E). Some cases exhibit a conspicuous periportal (zone 1 acinar) sparing of steatosis (D-F). Dashed lines indicate approximate demarcation between hepatocytes with and without fat droplets. cv, central vein; PT, portal tract.

lap biopsies demonstrated a higher prevalence of megamitochondria and slightly less macrovesicular steatosis (Table 3). For other histopathological features, the findings were intermediate between type 1 and type 2 NASH.

As shown in Table 2, children with type 1 and 2 NASH were different from one another in many important clinical and demographic aspects. Children with type 2 NASH were significantly younger ($P < .01$) and had a greater severity of obesity ($P < .05$) than children with type 1 NASH. Girls with type 2 NASH were even younger still, with a mean age of 10.5 years, versus 13.3 for girls with type 1 NASH. Boys were significantly ($P < .01$) more likely than girls to have type 2 NASH (58% vs. 36%). Furthermore, boys were less likely than girls to have type 1 NASH (9% vs. 31%). The distribution of histological patterns also differed significantly ($P < .001$) by race and ethnicity. Biopsies from children of black race mostly had simple steatosis. In contrast, the majority (64%) of biopsies from children of white race had type 1 NASH. Type 2 NASH was predominant among children of Asian or Native American race and those of Hispanic ethnicity. Laboratory values did not differ between subjects with type 1 and type 2 NASH.

Discussion

This study represents the largest biopsy series of pediatric NAFLD and demonstrates a histological spectrum ranging from simple steatosis to NASH and cirrhosis. The histological profile most commonly observed was a combination of severe steatosis with mild portal inflammation and fibrosis. By applying the methodology of cluster analysis, we demonstrated distinct histological patterns, including two different forms of steatohepatitis. We further determined that age, sex, race, ethnicity, and severity of obesity all associate with the steatohepatitis pattern types.

The traditional histopathology definitions of steatohepatitis include a combination of steatosis with balloon-

Table 3. Distribution of Histopathological Features in Pediatric NAFLD

Feature	All Subjects (n = 100)	Simple Steatosis (n = 16)	Overlap (n = 16)	Type 1 NASH (n = 17)	Type 2 NASH (n = 51)
Ballooning	24	0	56	77	0
Glycogen nuclei	55	44	44	41	51
Iron	3	0	0	0	6
Lipofuschin	6	0	0	12	8
Lipogranuloma	83	69	75	53	82
Lobular inflammation	36	0	31	71	22
Mallory	19	6	31	41	10
Megamitochondria	6	0	25	0	6
Perisinusoidal fibrosis	30	0	56	71	0
Portal inflammation	70	0	88	0	94
Portal fibrosis	60	0	63	0	84
Steatosis, mean (SD), %					
Macrovesicular	44 (28)	28 (27)	37 (25)	44 (26)	49 (27)
Microvesicular	17 (19)	29 (26)	14 (16)	20 (15)	15 (17)

NOTE. Values shown represent the percentage of subjects within a category who have the indicated feature. One exception is steatosis—the values shown reflect the mean percentage of hepatocytes with macrovesicular or microvesicular steatosis.

ing degeneration, Mallory hyaline, lobular inflammation, or pericellular fibrosis. The latter features localize to zone 3 and suggest evidence of liver cell injury. This pattern is associated with progression of fibrosis in adults.[19] Based on these criteria, only 20% of the biopsies in this study would be considered diagnostic of NASH, yet a majority show portal fibrous expansion, which is suggestive of early progression of liver disease. Furthermore, the presence of advanced fibrosis and cirrhosis in 8% of these patients supports the contention that pediatric fatty liver disease can be serious. Our data show an association of moderate to severe steatosis with portal inflammation and portal fibrosis. These findings raise questions with regard to the definition of steatohepatitis in children. This linked group of histological findings may represent a distinct pathological pattern of NASH. We have proposed a schema of type 1 and type 2 NASH wherein type 1 represents classically described steatohepatitis similar to definitions in adult populations, and type 2 NASH is characterized by moderate to severe steatosis, portal inflammation, and portal fibrosis. This second pattern was most common in our cohort.

We speculate that adults also exhibit a pattern consistent with type 2 NASH that has been underappreciated. Several reports discussing liver histology from adult subjects with NAFLD mention portal inflammation or fibrosis,[20] and recently these have been proposed to be an additional pattern of NAFLD.[21] A careful review of multiple studies of NAFLD in adults suggests that a portal-based pattern or type 2 NASH is not unique to children. In a study of morbidly obese adults undergoing bariatric surgery, portal inflammation was reported in 24%.[22] In a series of adults with NAFLD that was notable for having a majority of male patients, portal inflammation was reported in 63% and portal fibrosis in 6%.[23] In a series of morbidly obese adults, 27 of 105 subjects had portal fibrosis.[20] In the majority (19/27) of those with portal fibrosis, it was present without zone 3 fibrosis but usually (16/19) with portal inflammation. In a series of 73 adults with a BMI greater than 25 kg/m^2 and fatty liver isolated, portal fibrosis was noted in 42%.[24] The severity of portal fibrosis correlated positively with a degree of steatotic hepatocyes greater than 40%. Abrams et al.[21] performed a case control study of 195 adults undergoing Roux-en-Y gastric bypass surgery. The majority were women (88.2%) and were of non-Hispanic ethnicity and white race (89.7%). They had a mean age of 40.8 years and a mean BMI of 47.9 kg/m^2. Isolated portal fibrosis was seen in 33% of subjects, and they were of slightly younger age (mean: 38.6 yr). In 5 of 23 (22%) with advanced fibrosis, there were no zone 3 features. The investigators hypothesized that a subset of morbidly obese progress to cirrhosis without zone 3 injuries. They further speculated that visceral adipose tissue provides mediators of injury directly via the portal vein.

While 92% of the children with NAFLD in the current study were obese, those children with type 2 NASH had a greater severity of obesity than those with type 1 NASH. This is consistent with the observation that many of the reports of histology that included patients with portal inflammation and/or fibrosis as prominent features of NAFLD or NASH were in adults at the extreme end of the weight spectrum undergoing surgical treatment of obesity. Excessive body fat may interact with or supersede other mechanisms of disease development and progression. Increased amounts of adipose tissue are associated with decreased production of adiponectin. Data from studies in mice and humans increasingly implicate insufficient adiponectin as a major factor in the development of fatty liver and steatohepatitis.[25-27] Another source of hepatoxic mediators may be bacterial proinflammatory products such as lipopolysaccharide from intestinal flora.[28] Recent evidence demonstrating the role of intestinal microflora in regulating total body fat stores raises the possibility that intestinal microbial ecology may vary with the degree of obesity.[29] The underlying relationship between the severity of obesity and liver histology may be clarified by determining the relationships between patterns of injury and the regionalization of adipose storage.

Several biopsies demonstrated marked metabolic zonation with prominent zone 3 and minimal zone 1 steatosis (Fig. 4D-E). The fibrosis in these biopsies was confined to the portal (zone 1) area. This indicates that the factors involved in formation of hepatocellular steatosis may not be the same as factors evoking fibrosis, and that steatosis in the portal area may not be requisite for fibrous deposition. Compartmentalization of steatosis may occur more readily in zone 3 hepatocytes as a result of relatively diminished oxygen tension or nutrient availability, or potentially as a result of their increased age or differentiation due to sinusoidal streaming.

Clinical series and population-based studies have suggested that NAFLD is more common in boys than girls.[2,8-11,30] Sex differences have been shown in an animal model of NASH, with male sex associated with more severe and diffuse injury.[31] Although speculative, sex hormones are attractive candidates for playing a role in the development of and/or protection from steatohepatitis. In women with polycystic ovary syndrome, hyperandrogenism as determined by hirsutism was shown to have a strong relationship to fatty liver independent of insulin sensitivity and BMI.[32] Furthermore, the antiestrogen drug tamoxifen is associated with the development of NASH in a subset of women with breast cancer. One

potential mechanistic explanation is that estrogen signaling pathways are involved in the genetic regulation of fatty acid flux and oxidation within the liver.[33] Mice with congenital estrogen deficiency develop fatty liver spontaneously and experience resolution of fatty liver with estrogen replacement.[34] In a recent case report of a novel defect in the aromatase gene, a 25-year-old man was described with steatohepatitis consistent with the type 2 pattern and was noted to have substantial improvement in liver histology with the initiation of estrogen replacement therapy.[35] In the current study, girls with type 2 NASH were several years younger than girls with type 1 NASH. Although Tanner staging was not recorded, girls with type 2 NASH were more likely to be prepubertal and thus have a hormone profile more similar to young boys with type 2 NASH. In contrast, girls with type 1 NASH were more likely to be postmenarchal and thus have higher estrogen levels. Future studies would benefit from detailed analyses of sexual maturation and hormone levels with NASH subtypes.

In the present study, type 2 NASH was the major form seen in children of Asian and Native American race. In a clinical population of young adult Iranians with NAFLD, the majority were men with biopsies characterized by moderate to severe steatosis and portal inflammation.[36] Similarly, in a group of adult Japanese patients with NAFLD, portal fibrosis was uniformly more common and more severe than pericellular fibrosis.[37] Furthermore, this pattern has also been reported to be more common in Japanese adults with alcoholic liver disease. Thus the interaction between common hepatotoxic insults such as obesity or alcohol is modified by race. It is not clear to what extent race serves as a marker of genetic factors versus a correlate of influential environmental factors.

The limitations of this study are related to the acquisition of a clinical population at a single center. Our subjects were predominantly of Hispanic ethnicity, and most of them were Mexican American boys. This is consistent with school-based epidemiology showing that among obese adolescents, male sex and Hispanic ethnicity are strong risk factors for abnormal ALT and suspected NAFLD.[30] Second, the majority of our subjects were selected for biopsy because of elevated ALT levels. This reflects widespread clinical practice patterns, because biopsies in children with NAFLD are usually performed in response to persistently elevated serum aminotransferase values. Therefore, little is known about NAFLD in children with normal ALT levels. However, we note that both type 1 and 2 NASH were seen in the few children in our study with normal serum aminotransferase levels. Finally, this was a cross-sectional study. To describe features in untreated patients, we only included index biopsies. To determine the histopathology of pediatric NAFLD in its natural history and in response to treatment, additional studies are required as will be performed by the National Institutes of Health NASH Clinical Research Network.[38,39]

The issue of when to perform a liver biopsy in children with suspected NAFLD remains controversial. The data from the current study demonstrate that the majority of children with biopsy-proven NAFLD have features of steatohepatitis. In adults with suspected NAFLD, the presence of diabetes and an age older than 40 years have been proposed as clinical indications for liver biopsy.[40, 41] The current findings suggest that neither age nor the presence of diabetes are likely to be useful determinants in children as those with advanced disease are slightly younger than those with milder disease and did not have type 2 diabetes. One laboratory value that may be useful is GGT as this was considerably higher in those children with stage 3 and 4 fibrosis. GGT may be serving as a marker of the metabolic syndrome. In addition to its role as a hepatobiliary enzyme, GGT is also a marker of oxidative stress.[42] In adults GGT has been shown to predict incident metabolic syndrome.[43] This deserves further attention in future studies. The relationship between the metabolic syndrome and NAFLD in children has not been characterized.

In conclusion, hypotheses regarding the pathophysiology of NAFLD and NASH propose many different factors in the development of steatosis, inflammation, and fibrosis.[44] One factor complicating the translation from animal models to humans is that NAFLD is likely to represent many different phenotypes that have overlapping and nonoverlapping elements. Identification of the subphenotypes of NAFLD will augment efforts to determine causation and cure. We conclude that type 1 and type 2 NASH are distinct subtypes of pediatric NAFLD and that type 2 NASH is the more common pattern in children. Key differences between these subtypes include age, sex, race/ethnicity, and severity of obesity. The biological underpinnings of these subtypes remain to be elucidated. Importantly, the majority of children with advanced fibrosis demonstrate the type 2 NASH pattern. These findings have important implications for studies of the pathophysiology, genetics, natural history, and response to treatment in pediatric NAFLD. Investigators should recognize these subtypes when planning and analyzing such studies. Similarly, hepatologists and pathologists should note these differences when interpreting liver biopsies in children with NAFLD.

References

1. Lavine JE, Schwimmer JB. Pediatric non-alcoholic steatohepatitis. In: Farrell G, George J, Hall P, McCollough A, eds. Non-alcoholic Steatohepatitis. Oxford, England: Blackwell Publishing, 2004:229-240.

2. Schwimmer JB, Deutsch R, Rauch JB, Behling C, Newbury R, Lavine JE. Obesity, insulin resistance, and other clinicopathological correlates of pediatric nonalcoholic fatty liver disease. J Pediatr 2003;143:500-505.
3. Kimm SY, Obarzanek E. Childhood obesity: a new pandemic of the new millennium. Pediatrics 2002;110:1003-1007.
4. Suzuki D, Hashimoto E, Kaneda K, Tokushige K, Shiratori K. Liver failure caused by non-alcoholic steatohepatitis in an obese young male. J Gastroenterol Hepatol 2005;20:327-329.
5. Brunt EM, Janney CG, Di Bisceglie AM, Neuschwander-Tetri BA, Bacon BR. Nonalcoholic steatohepatitis: a proposal for grading and staging the histological lesions. Am J Gastroenterol 1999;94:2467-2474.
6. Brunt EM. Nonalcoholic steatohepatitis: definition and pathology. Semin Liver Dis 2001;21:3-16.
7. Brunt EM, Tiniakos DG. Pathology of steatohepatitis. Best Pract Res Clin Gastroenterol 2002;16:691-707.
8. Moran JR, Ghishan FK, Halter SA, Greene HL. Steatohepatitis in obese children: a cause of chronic liver dysfunction. Am J Gastroenterol 1983; 78:374-377.
9. Baldridge AD, Perez-Atayde AR, Graeme-Cook F, Higgins L, Lavine JE. Idiopathic steatohepatitis in childhood: a multicenter retrospective study. J Pediatr 1995;127:700-704.
10. Rashid M, Roberts EA. Nonalcoholic steatohepatitis in children. J Pediatr Gastroenterol Nutr 2000;30:48-53.
11. Manton ND, Lipsett J, Moore DJ, Davidson GP, Bourne AJ, Couper RT. Non-alcoholic steatohepatitis in children and adolescents. Med J Aust 2000;173:476-479.
12. Schwimmer JB, Behling C, Newbury R, et al. The histological features of pediatric nonalcoholic fatty liver disease (NAFLD). HEPATOLOGY 2002; 36:412A.
13. Ferrannini E, Natali A, Bell P, Cavallo-Perin P, Lalic N, Mingrone G. Insulin resistance and hypersecretion in obesity. European Group for the Study of Insulin Resistance (EGIR). J Clin Invest 1997;100:1166-1173.
14. Katz A, Nambi SS, Mather K, Baron AD, Follmann DA, Sullivan G, et al. Quantitative insulin sensitivity check index: a simple, accurate method for assessing insulin sensitivity in humans. J Clin Endocrinol Metab 2000;85: 2402-2410.
15. Uwaifo GI, Fallon EM, Chin J, Elberg J, Parikh SJ, Yanovski JA. Indices of insulin action, disposal, and secretion derived from fasting samples and clamps in normal glucose-tolerant black and white children. Diabetes Care 2002;25:2081-2087.
16. Hrebicek J, Janout V, Malincikova J, Horakova D, Cizek L. Detection of insulin fesistance by simple quantitative insulin sensitivity check index QUICKI for epidemiological assessment and prevention. J Clin Endocrinol Metab 2002;87:144-147.
17. Kaufmann L, Rousseeuw PJ. Finding groups in data: an introduction to cluster analysis. New York: John Wiley, 1990.
18. Reiner AP, Ziv E, Lind DL, Nievergelt CM, Schork NJ, Cummings SR, et al. Population structure, admixture, and aging-related phenotypes in African American adults: the cardiovascular health study. Am J Hum Genet 2005;76:463-477.
19. Matteoni CA, Younossi ZM, Gramlich T, Boparai N, Liu YC, McCullough AJ. Nonalcoholic fatty liver disease: a spectrum of clinical and pathological severity. Gastroenterology 1999;116:1413-1419.
20. Dixon JB, Bhathal PS, O'Brien PE. Nonalcoholic fatty liver disease: predictors of nonalcoholic steatohepatitis and liver fibrosis in the severely obese. Gastroenterology 2001;121:91-100.
21. Abrams GA, Kunde SS, Lazenby AJ, Clements RH. Portal fibrosis and hepatic steatosis in morbidly obese subjects: A spectrum of nonalcoholic fatty liver disease. HEPATOLOGY 2004;40:475-483.
22. Marceau P, Biron S, Hould FS, Marceau S, Simard S, Thung SN, et al. Liver pathology and the metabolic syndrome X in severe obesity. J Clin Endocrinol Metab 1999;84:1513-1517.
23. Bacon BR, Farahvash MJ, Janney CG, Neuschwander-Tetri BA. Nonalcoholic steatohepatitis: an expanded clinical entity. Gastroenterology 1994;107:1103-1109.
24. Ratziu V, Giral P, Charlotte F, Bruckert E, Thibault V, Theodorou I, et al. Liver fibrosis in overweight patients. Gastroenterology 2000;118:1117-1123.
25. Xu A, Wang Y, Keshaw H, Xu LY, Lam KSL, Cooper GJS. The fat-derived hormone adiponectin alleviates alcoholic and nonalcoholic fatty liver diseases in mice. J Clin Invest 2003;112:91-100.
26. Targher G, Bertolini L, Zenari L. Hypoadiponectinemia is closely associated with nonalcoholic hepatic steatosis in obese subjects. Diabetes Care 2004;27:2085-2086.
27. Kaser S, Moschen A, Cayon A, Kaser A, Crespo J, Pons-Romero F, et al. Adiponectin and its receptors in non-alcoholic steatohepatitis. Gut 2005; 54:117-121.
28. Yang SQ, Lin HZ, Lane MD, Clemens M, Diehl AM. Obesity increases sensitivity to endotoxin liver injury: implications for the pathogenesis of steatohepatitis. Proc Natl Acad Sci U S A 1997;94:2557-2562.
29. Backhed F, Ding H, Wang T, Hooper LV, Koh GY, Nagy A, Semenkovich CF, et al. The gut microbiota as an environmental factor that regulates fat storage. Proc Natl Acad Sci U S A 2004;101:15718-15723.
30. Schwimmer JB, McGreal N, Deutsch R, Finegold M, Lavine JE. The Influence of gender, race, and ethnicity on suspected fatty liver in obese adolescents. Pediatrics 2005;115:e561-e565.
31. Kirsch R, Clarkson V, Shephard EG, Marais DA, Jaffer MA, Woodburne VE, et al. Rodent nutritional model of non-alcoholic steatohepatitis: species, strain and sex difference studies. J Gastroenterol Hepatol 2003;18: 1272-1282.
32. Schwimmer JB, Khorram O, Chiu V, Schwimmer WB. Abnormal aminotransferase activity in women with polycystic ovary syndrome. Fertil Steril 2005;83:494-497.
33. Nemoto Y, Toda K, Ono M, et al. Altered expression of fatty acid-metabolizing enzymes in aromatase-deficient mice. J Clin Invest 2000;105:1819-1825.
34. Hewitt KN, Pratis K, Jones MEE, Simpson ER. Estrogen replacement reverses the hepatic steatosis phenotype in the male aromatase knockout mouse. Endocrinology 2004;145:1842-1848.
35. Maffei L, Murata Y, Rochira V, Tubert G, Aranda C, Vazquez M, et al. Dysmetabolic syndrome in a man with a novel mutation of the aromatase gene: effects of testosterone, alendronate, and estradiol treatment. J Clin Endocrinol Metab 2004;89:61-70.
36. Bahrami H, Daryani NE, Mirmomen S, Kamangar F, Haghpanah B, Djalili M. Clinical and histological features of nonalcoholic steatohepatitis in Iranian patients. BMC Gastroenterol 2003;3:27-33.
37. Nonomura A, Mizukami Y, Unoura M, Kobayashi K, Takeda Y, Takeda R. Clinicopathologic study of alcohol-like liver disease in non-alcoholics; non-alcoholic steatohepatitis and fibrosis. Gastroenterol Jpn 1992;27:521-528.
38. Lavine JE, Schwimmer JB. Pediatric initiatives within the Nonalcoholic Steatohepatitis-Clinical Research Network (NASH CRN). J Pediatr Gastroenterol Nutr 2003;37:220-221.
39. Kleiner DE, Brunt EM, Van Natta M, Behling C, Contos MJ, Cummings OW, et al. Design and validation of a histological scoring system for nonalcoholic fatty liver disease. HEPATOLOGY 2005;41:1313-1321.
40. Angulo P, Keach JC, Batts KP, Lindor KD. Independent predictors of liver fibrosis in patients with nonalcoholic steatohepatitis. HEPATOLOGY 1999; 30:1356-1362.
41. McCullough AJ. Update on nonalcoholic fatty liver disease. J Clin Gastroenterol 2002;34:255-262.
42. Lee DH, Ha MH, Kim JH, Christiani DC, Gross MD, Steffes M, et al. Gamma-glutamyltransferase and diabetes—a 4 year follow-up study. Diabetologia 2003;46:359-364.
43. Nakanishi N, Suzuki K, Tatara K. Serum γ-glutamyltransferase and risk of metabolic syndrome and type 2 diabetes in middle-aged Japanese men. Diabetes Care 2004;27:1427-1432.
44. Browning JD, Horton JD. Molecular mediators of hepatic steatosis and liver injury. J Clin Invest 2004;114:147-152.